



# Subacute *Aerococcus urinae* Infective Endocarditis With Mycotic Aneurysms in a Pediatric Patient: Case Report and Literature Review

Natalie Sous,<sup>1</sup> Julia A. Piwoz,<sup>2</sup> Aryeh Z. Baer,<sup>2</sup> and Sejal Makvana Bhavsar<sup>2</sup>

<sup>1</sup>Rutgers New Jersey Medical School, Medicine and Pediatrics, Newark, New Jersey; and <sup>2</sup>Joseph M. Sanzari Children's Hospital at Hackensack Meridian Health, Hackensack, New Jersey

*Aerococcus urinae* has been found to cause urinary tract infection in elderly patients and has been reported as a rare cause of infective endocarditis associated with significant morbidity and death in adults. However, information regarding its occurrence in children is lacking. We report here the case of a pediatric patient with subacute *A urinae* infective endocarditis with mycotic aneurysms.

## CASE PRESENTATION

An 11-year-old boy with a medical history significant for an unrepaired ventricular septal defect (VSD) and imperforate anus repaired in infancy presented to our hospital with a 2-month history of fever and cough. His fevers started initially in association with pharyngitis, and his pediatrician treated him for streptococcal pharyngitis, followed by oseltamivir for presumed influenza infection. After 1 month of ongoing fever, he was admitted to our hospital with bilateral pneumonia, for which he was treated with ceftriaxone and azithromycin. He was discharged home after 4 days on cefdinir to complete a 10-day course of antibiotics. After discharge, he continued to have daily fevers. He returned to our emergency department 3 weeks later with complaints of fever, right-sided chest pain, shortness of breath, and emesis. He reported night sweats, and he had lost 5 lb as a result of poor appetite. In the emergency department, he was febrile (102.9°F), tachycardic (169 beats per minute), and normotensive. His oxygen saturation was 96% on room air. He appeared thin but was not toxic appearing and was in no acute distress. Results of a physical examination were notable for bilateral supraclavicular lymphadenopathy, coarse bilateral breath sounds, a harsh grade 4/6 holosystolic murmur, right and left upper-quadrant abdominal tenderness, and hepatomegaly. Laboratory testing revealed a white blood cell count of  $14.8 \times 10^3/\mu\text{L}$  (83% neutrophils, 9% lymphocytes, 7%

monocytes), a hemoglobin of concentration of 7.4 g/dL, and a platelet count of  $156 \times 10^3/\mu\text{L}$ . His erythrocyte sedimentation rate was 60 mm/hour, and his C-reactive protein level was 15.6 mg/dL. The results of his creatinine and liver function tests were within reference values. The results of a respiratory-pathogen panel by polymerase chain reaction assay were negative for all targets, and his urinalysis results were normal. Chest radiography revealed worsening (compared to the previous study) multilobar airspace opacities. Chest computed tomography (CT) revealed extensive bilateral pulmonary nodular infiltrates, some with cavitation, in association with bilateral hilar, subcarinal, paratracheal, and supraclavicular lymphadenopathy. He was given a dose of ceftriaxone and admitted to the general pediatrics inpatient unit for further management. Vancomycin was added the following day because a culture of his blood, started at admission, was reported to be growing Gram-positive cocci in clusters. These cocci were subsequently identified by matrix-assisted laser desorption ionization time-of-flight mass spectrometry as *Aerococcus urinae*. In a review of the records from his previous admission, he was noted at that time to have had a single positive blood culture result for *A urinae*. This organism was presumed to be a contaminant, because only 1 of his 2 blood cultures grew, and he was not treated for the infection. Although he had prolonged fevers and predisposing heart disease, echocardiography was not performed. During that previous admission, only chest radiography was performed, and it revealed patchy multifocal airspace disease in the mid and lower lungs bilaterally; he therefore was treated for pneumonia. After further questioning, the patient's mother reported that at the time of fever onset, the boy had had foul-smelling urine that had since resolved. *A urinae* was recovered from cultures on blood collected on 4 successive days after treatment was initiated. The minimum inhibitory concentration for penicillin G was 0.047 mg/L. His antibiotic

Received 17 October 2018; editorial decision 5 February 2019; accepted 9 February 2019; Published online March 6, 2019.

Correspondence: S. M. Bhavsar, MD, Joseph M. Sanzari Children's Hospital at Hackensack Meridian Health, 30 Prospect Ave, Hackensack, NJ 07601 (sejalmakvana@gmail.com).

Journal of the Pediatric Infectious Diseases Society 2019;8(5):492–494

© The Author(s) 2019. Published by Oxford University Press on behalf of The Journal of the Pediatric Infectious Diseases Society. All rights reserved. For permissions, please e-mail: journals.permissions@oup.com.

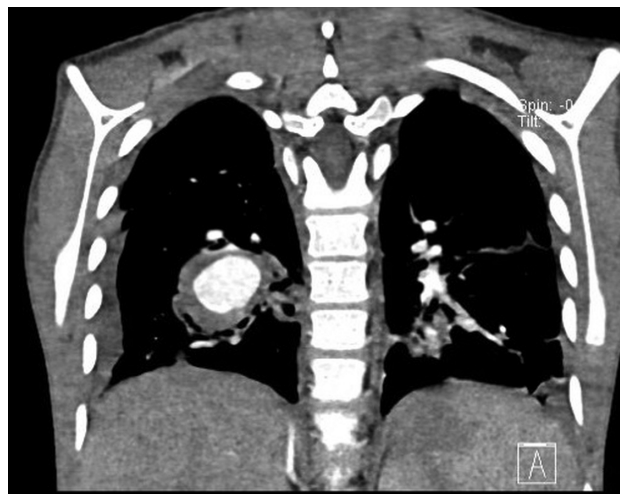
DOI: 10.1093/jpids/piz016

regimen was changed to penicillin G and gentamicin. His initial echocardiogram was notable for findings associated with his known septal defect, which was obstructed by accessory tricuspid valve tissue but did not show obvious vegetations. Despite sterilization of blood cultures, he continued to have fevers and chest pain. Repeat echocardiography revealed a partially closed VSD; it was difficult to ascertain if it was obstructed by a sessile mass or excessive valve tissue. A CT scan showed findings concerning for a large mycotic aneurysm. CT angiography confirmed the presence of a large (3.4 × 2.4-cm) lobulated mycotic aneurysm of the right lower lobe pulmonary artery and a smaller (1.0 × 0.8-cm) left lower lobe pulmonary artery aneurysm (Figures 1 and 2). It also revealed an increase in multiple bilateral pulmonary nodules and consolidations, many with new areas of cavitation. Because of the presence of large aneurysms, the patient was transferred on hospital day 12 to an outside hospital with pediatric cardiothoracic surgery services. During his stay in that hospital, echocardiography continued to show the VSD, which was partially closed by aneurysmal tricuspid tissue, and a likely tricuspid valve vegetation closing the VSD. Follow-up CT angiography 1 week after his transfer revealed interval growth of his right-sided aneurysm (5.3 × 4.1 cm), but no left pulmonary artery aneurysm was identified. The patient subsequently underwent a right thoracotomy and right lower lobectomy. Operative findings included a perforation in the pulmonary artery with some debris in it that was consistent with an infected embolism. Cultures of tissue taken during surgery did not grow any bacteria. He tolerated the procedure well and was discharged home on postoperative day 16 with a plan to repair his VSD at a later date. He completed a 6-week course of antibiotic therapy with penicillin G and, at the time of this writing, had not suffered a relapse.

## DISCUSSION

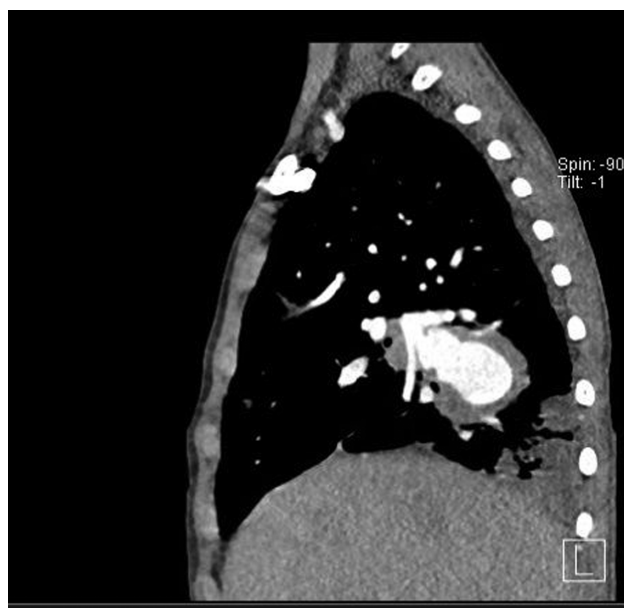
*A urinae* has been reported to be a causative agent of urinary tract infection in adults, especially those with an underlying urinary tract pathology. Although rare, severe infections, including bacteremia, osteomyelitis, and endocarditis, caused by *A urinae* have also been reported in adult populations [1–3]. Nearly all patients with bacteremia have had a focus in the urinary tract, and the infection in one-third of patients with septicemia has been complicated by endocarditis. Endocarditis caused by *A urinae* in up to 40 adult patients has been reported and has a high mortality rate, although the reported patients have tended to be elderly and have multiple comorbidities [4–8].

*A urinae* has been implicated also in urinary tract infection in pediatric patients. In case reports, these children typically report foul-smelling urine as the primary symptom [9]. We suspect that because our patient had foul-smelling urine at the start of his



**Figure 1.** Computed tomography angiogram showing the presence of a large lobulated mycotic aneurysm of the right lower lobe pulmonary artery and a smaller left lower lobe pulmonary artery aneurysm.

illness, he likely initially had a urinary tract infection, although results of the urine culture performed at our facility were negative. This finding is consistent with previous reports of *A urinae* infective endocarditis in adult men with a complicated urinary pathology, such as prostate cancer, and urinary symptoms with negative urine culture results [2, 8]. Very few cases of severe systemic infections caused by *A urinae* in the pediatric population have been reported. A case of aortic valve endocarditis caused by *A urinae* in a 17-year-old patient was reported recently [10]. Similar to our patient, that patient had a congenital heart defect as a predisposing factor for endocardial infection. The patient also reported



**Figure 2.** Computed tomography angiogram, side view.

foul-smelling urine but had a negative urine culture result and during his admission was found incidentally to have a urinary stricture. One other case of uncomplicated *A urinae* bacteremia in a 14-year-old with acute myeloid leukemia was reported [11]. At this time, to our knowledge, no other case reports of systemic *A urinae* infection in a pediatric patient exist in the literature.

Although *A urinae* infection in adult and pediatric populations is rare, it is important to note that the prevalence of aerococci might be underreported. Aerococci are Gram-positive organisms that produce  $\alpha$ -hemolysis on blood agar and are catalase negative, so they might be misidentified as  $\alpha$ -hemolytic streptococci [1, 2, 12, 13]. It has been suggested also that it is underreported in urine culture results, because urine cultures are not often grown in the CO<sub>2</sub>-rich environments that are favorable for the growth of aerococci [2]. With the increased use of matrix-assisted laser desorption ionization time-of-flight mass spectrometry, aerococci can now be identified more accurately [1, 2, 12].

Our patient had 4 days of consecutive positive blood culture results despite appropriate treatment, which suggests a complicated infection. On the basis of the modified Duke criteria, our patient fulfilled 1 major criterion (2 separate positive blood culture results) and 3 minor criteria (predisposing heart condition, fever [temperature of >38°C], and vascular phenomena in the form of a mycotic aneurysm) [14]. Although our patient's initial transthoracic echocardiogram results were negative for any obvious vegetation, follow-up echocardiography revealed excessive valve tissue that, in this setting, was likely a sessile mass or vegetation. During his first hospitalization, our patient had only 1 positive blood culture result, so he would not have fulfilled diagnostic criteria at that time; however, only 2 blood cultures were performed, and cardiac echocardiography was not performed. In a study by Senneby et al [12], 49 patients with *A urinae* bacteremia were identified, and 22 (45%) of them grew the bacterium in 1 of 2 blood cultures. Aerococci are now increasingly recognized as human pathogens, and growth in a culture bottle should be considered evidence of a true infection. Infectious endocarditis should always be suspected in cases of aerococcal bacteremia, especially those with *A urinae*; therefore, another workup for endocarditis should have been performed during the first hospital stay for our patient [12].

The majority of the reported patients with *A urinae* endocarditis have been treated with a  $\beta$ -lactam agent along with an aminoglycoside for synergy [1, 2, 7, 8, 12, 13]. The Clinical and Laboratory Standards Institute (CLSI) (August 2016) and European Committee on Antimicrobial Susceptibility Testing (EUCAST) (January 2017) have currently established

species-specific break points for *A urinae* and *Aerococcus sanguinicola*. Isolates of these species are reportedly susceptible to penicillin, cefotaxime, meropenem, vancomycin, linezolid, and rifampin [15]. The penicillin G minimum inhibitory concentration for our patient's culture isolate was 0.047 mg/L, which is in the susceptible range according to CLSI interpretation and EUCAST break points.

To our knowledge, ours is the first pediatric patient with *A urinae* endocarditis complicated by mycotic aneurysms to be reported. With improved technology used to identify aerococci in cultures, the prevalence of reported systemic infections might rise.

## Note

**Potential conflicts of interest.** All authors: No reported conflicts of interest. All authors have submitted the ICMJE Form for Disclosure of Potential Conflicts of Interest. Conflicts that the editors consider relevant to the content of the manuscript have been disclosed.

## References

- Rasmussen M. Aerococci and aerococcal infections. *J Infect* **2013**; 66:467–74.
- Rasmussen M. *Aerococcus*: an increasingly acknowledged human pathogen. *Clin Microbiol Infect* **2016**; 22:22–7.
- De Jong MF, Soetekouw R, ten Kate RW, Veenendaal D. *Aerococcus urinae*: severe and fatal bloodstream infections and endocarditis. *J Clin Microbiol* **2010**; 48:3445–7.
- Siddiqui B, Chaucer B, Chevenon M, et al. *Aerococcus urinae* associated aortic and tricuspid valve infective endocarditis. *IDCases* **2016**; 4:30–1.
- Tathireddy H, Settypalli S, Farrell JJ. A rare case of *Aerococcus urinae* infective endocarditis. *J Community Hosp Intern Med Perspect* **2017**; 7:126–9.
- Christensen JJ, Jensen IP, Faerk J, et al; Danish ALO Study Group. Bacteremia/septicemia due to *Aerococcus*-like organisms: report of seventeen cases. *Clin Infect Dis* **1995**; 21:943–7.
- Zbinden R, Santanam P, Hunziker L, et al. Endocarditis due to *Aerococcus urinae*: diagnostic tests, fatty acid composition and killing kinetics. *Infection* **1999**; 27:122–4.
- Sunnerhagen T, Nilson B, Olaison L, Rasmussen M. Clinical and microbiological features of infective endocarditis caused by aerococci. *Infection* **2015**; 44:167–73.
- Lenherr N, Berndt A, Ritz N, Rudin C. *Aerococcus urinae*: a possible reason for malodorous urine in otherwise healthy children. *Eur J Pediatr* **2014**; 173:1115–7.
- Qureshi NK, Ekta P. *Aerococcus urinae* as the causative agent in infective endocarditis of the aortic valve in a pediatric patient. *Pediatr Infect Dis J* **2018**; 37:1065–6.
- Colakoglu S, Turunc T, Taskoparan M, et al. Three cases of serious infection caused by *Aerococcus urinae*: a patient with spontaneous bacterial peritonitis and two patients with bacteremia. *Infection* **2008**; 36:288–90.
- Senneby E, Göransson L, Weiber S, Rasmussen M. A population-based study of aerococcal bacteraemia in the MALDI-TOF MS-era. *Eur J Clin Microbiol Infect Dis* **2016**; 35:755–62.
- Senneby E, Petersson AC, Rasmussen M. Epidemiology and antibiotic susceptibility of aerococci in urinary cultures. *Diagn Microbiol Infect Dis* **2015**; 81:149–51.
- Li JS, Sexton DJ, Mick N, et al. Proposed modifications to the Duke criteria for the diagnosis of infective endocarditis. *Clin Infect Dis* **2000**; 30:633–8.
- Carkaci D, Nielsen XC, Fuursted K, et al. *Aerococcus urinae* and *Aerococcus sanguinicola*: susceptibility testing of 120 isolates to six antimicrobial agents using disk diffusion (EUCAST), Etest, and broth microdilution techniques. *Open Microbiol J* **2017**; 11:160–6.